

Case Study #9

DISCLAIMER: These pictures are original and are **NOT** to be used anywhere else **WITHOUT my written permission**. Not on any website, publication, etc. This site is now officially copyrighted.

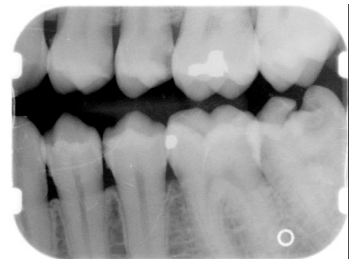
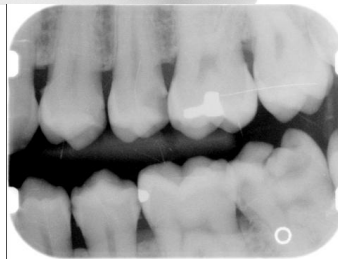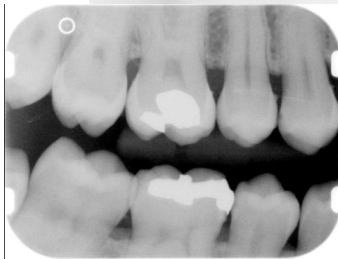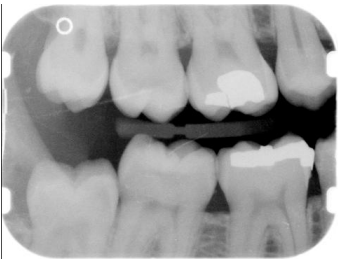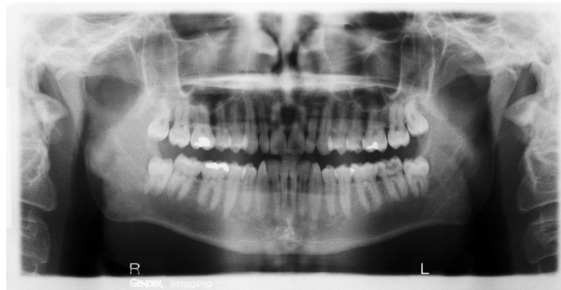Age:
22 M

Medical History:
No problems, meds
Smoker

Dental History:
It has been 5 years since last dental visit.

Xrays before treatment:

You can click on any pic to see a larger view



Intraoral pics before tx:

None on this pt, sorry :(

Perio Charting:
bottom line is initial visit

Date	1	2	3	4	5	6	7	8	9	10	11	12	13	14	15	16
B	5 4 5	5 4 4	4 4 4	4 3 3	3 3 3	3 2 3	3 2 2	2 2 3	3 2 3	3 2 3	3 3 3	3 3 3	3 3 4	4 3 4	4 3 4	
L	5 4 5	5 4 5	5 4 4	5 4 5	5 4 4	6 4 4	3 2 2	2 2 2	2 2 2	2 2 2	2 2 4	4 4 5	5 4 5	5 4 5	5 4 5	5 4 3
L	4 3 4	4 3 4	4 3 3	3 3 3	3 3 3	3 2 3	3 2 3	3 2 3	3 2 3	3 2 3	3 2 3	3 3 3	3 3 4	4 3 4	4 3 4	
B	5 4 5	5 4 5	5 4 5	5 4 4	4 3 3	3 2 2	2 2 2	2 2 2	2 2 3	3 2 3	3 2 4	5 4 4	4 4 5	5 4 5	5 5 6	
L	4 3 4	4 3 4	4 3 4	4 3 4	4 3 4	3 2 3	3 2 3	3 2 3	3 2 3	3 2 3	3 3 3	3 3 4	4 4 4	4 4 4	4 4 5	5 5
B	5 4 5	5 4 5	5 4 5	5 4 5	5 3 3	3 2 3	3 2 3	3 2 3	3 2 3	3 2 3	3 2 3	4 4 5	5 4 6	6 4 6	6 6 6	
B	4 3 4	4 3 4	4 3 3	3 3 3	3 2 3	4 3 4	4 3 3	3 3 3	3 3 3	3 3 4	4 3 4	4 3 4	4 3 4	4 3 4	4 3 4	4 4 4
B	5 4 5	5 4 5	5 4 5	5 4 5	5 4 4	4 2 3	3 3 3	3 2 3	3 2 2	2 2 2	2 2 2	5 4 4	4 4 5	5 4 6	6 4 4	6 6
	32	31	30	29	28	27	26	25	24	23	22	21	20	19	18	17

Summary Data Comparison

Date	Bleeding		Suppuration		Furcation		Mobility	PD > Alert		CAL < 0		CAL 1-3		CAL 4-5		CAL 6+	
	Teeth	Sites	Teeth	Sites	Teeth	Sites	Teeth	Teeth	Sites	Teeth	Sites	Teeth	Sites	Teeth	Sites	Teeth	Sites
23	51	0	0	0	0	0	0	21	67	0	0	30	118	21	67	0	0
0	0	0	0	0	0	0	0	22	108	0	0	15	71	21	96	6	12

Treatment:

- Initial Exam, FMX by dentist
From this point on, just discussing dental hygiene appts.
(3rd molars were rec. to be removed)
Perio chart
Gen. inflammation
Heavy stain, heavy supragingival and subgingival calculus
OHI -- daily flossing, Exp to pt that he is starting to show signs of periodontal disease, etiology of disease, etc. Exp to pt that bleeding is not a healthy sign.
VERY NICE!
- 2nd visit -- SRP UR, LR (2 quads 04341)
Anesthesia was administered
Heavy calculus, tenacious -- very hard to remove IP -- very grainy and tenacious
Gen. inflammation -- very boggy around #1
Mod plaque
Extremely heavy hemo w/scaling
Rev. homecare, exp to pt that I may redo right side @ fine scale appt.
- 3rd visit -- SRP LL 04341
Pt was already numb due to RCT
decay on #18 is inhibiting scaling due to scaler getting stuck
Heavy calculus, tenacious
Mod plaque
Heavy hemo w/scaling
Rev. homecare
Stannous FI2 Rinse was given to pt.

- 4th visit -- SRP UL 04341
Anesthesia was administered
Heavy calculus, tenacious
Mod plaque
Heavy hemo w/scaling
Rev. homecare
Pt insurance maxed out, chooses to wait until new year to remove 3rds.
- 5th visit -- reeval -- periodontal maintenance -- 04910
Pt is using fl2 at home
Slight inflammation but very much improved
It plaque, calculus
probed, areas have improved
Rev. homecare, exp importance and need for 4 MRC
- will keep case updated.

What would you have done in this case?

Please leave let me know by emailing me to amyrdh@aol.com.

