

Case Study #6

DISCLAIMER: These pictures are original and are **NOT** to be used anywhere else **WITHOUT my written permission**. Not on any website, publication, etc. This site is now officially copyrighted.

Age:
35

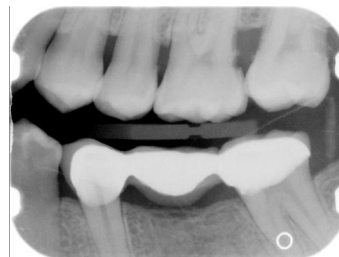
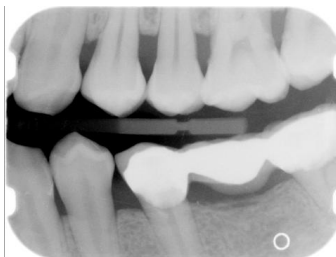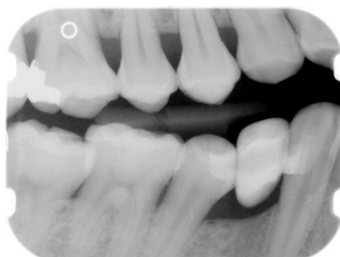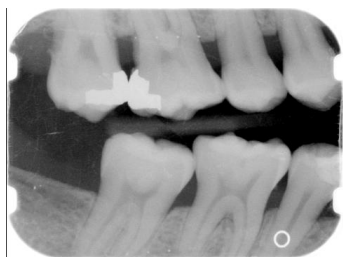Medical History:
No problems, meds
Non-smoker

Dental History:
SRP was done in 2002 in a different office by the DDS

Xrays before treatment:

You can click on any pic to see a larger view

Only bxw were taken due to pt having an FMX taken at previous office a year before. We requested xrays. SRP was done in previous office a year before by a DDS.



Intraoral pics before tx:

None on this pt, sorry :(

Perio Charting:

Date	1	2	3	4	5	6	7	8	9	10	11	12	13	14	15	16
2		5 4 5	5 5 5	5 4 5	5 4 5	4 3 4	4 3 3	3 2 3	3 2 3	3 3 3	3 3 4	4 3 4	4 3 5	5 3 8	8 3 6	
		5 3 5	5 3 5	5 3 5	5 3 4	4 3 4	4 3 4	4 3 4	4 3 4	4 3 4	4 3 4	4 3 4	5 3 6	6 3 8	8 3 6	
		5 3 5	5 3 5	5 3 5		5 3 4	4 3 4	4 3 4	4 3 4	4 3 4	4 3 4	4 3 5	5 3 5		5 3 5	
		5 4 4	5 4 5	4 4 4		4 3 5	5 3 4	4 3 5	5 3 4	4 3 4	4 3 5	5 3 5	5 3 5		5 3 5	
	32	31	30	29	28	27	26	25	24	23	22	21	20	19	18	17

Summary Data Comparison

Date	Bleeding		Suppuration		Furcation		Mobility	PD > Alert		CAL < 0		CAL 1-3		CAL 4-5		CAL 6+	
	Teeth	Sites	Teeth	Sites	Teeth	Sites	Teeth	Teeth	Sites	Teeth	Sites	Teeth	Sites	Teeth	Sites	Teeth	Sites
	0	0	0	0	0	0	0	26	156	0	0	26	53	25	95	3	8

Treatment:

- Initial appt with dentist (from this point on, only covering the hygiene appts.)
- 1st visit -- SRP UR -- 04341
Periocharting
Heavy subgingival calculus, heavy marginal and IP plaque, teeth completely covered with thick plaque
Anesthesia administered
Gen. inflammation
Extremely heavy hemo both w/ probing (all areas bled) and scaling
Pt had peridex from SRP in 2002 but never used it
Pt didn't speak English, got patient education in her language on www.dentalcare.com and also had her husband speak to her.
Ultrasonics and handscaling used
- 2nd visit -- UL, LL (2 quads -- 04341)
Heavy subgingival calculus, heavy marginal and IP plaque, teeth completely covered with thick plaque
Anesthesia administered
Gen. inflammation
Extremely heavy hemo w/scaling
Arestin placed on 14 and 15
Heavy black tenacious both burnished and residual -- very hard to remove
14D still rough
Maxillary injections made pt sensitive
Rec warm salt water rinses
Rev. of homecare with husband to exp to pt. Rec sonicare but husband declines
- 3rd visit -- LR -- 04341
Heavy subgingival calculus, heavy marginal and IP plaque, teeth completely covered with thick plaque
Anesthesia administered
Gen. inflammation
Extremely heavy hemo w/scaling
Pt is not taking care of her teeth at home
Left side quads have heavy plaque and calculus reforming.
Reprinted out information from www.dentalcare.com
- 4th visit -- 4 weeks reeval -- 04910
Probed
Heavy plaque
Heavy hemo
Mod supragingival calculus
14 and 15 completely covered in heavy thick plaque
Pt has sensitivity -- gave pt control rx toothpaste to use for sensitivity
Rev. homecare
Dentist came in to examine pt, tried to exp to husband that she is not keeping up with homecare and needs to in order to get the disease under control
- 5th visit -- 3 months later -- 04910
Probed
Heavy plaque
Heavy hemo

Mod supragingival calculus

Very heavy food impaction

Periodontal prognosis poor due to non-compliance with homecare -- not stabilized.

- 6th visit -- 3 months later -- 04910

probed

Heavy plaque

Heavy hemo

Mod supragingival calculus

Mod subgingival calculus

Very heavy food impaction

Referral was given to pt to go to periodontist due to disease not being stabilized. Pt made appt for periodontist at our office.

- NA -- will see recommendations from periodontist.

What would you have done in this case?

Please leave let me know by emailing me to amyrdh@aol.com.

