

Case Study #5

DISCLAIMER: These pictures are original and are **NOT** to be used anywhere else **WITHOUT my written permission**. Not on any website, publication, etc. This site is now officially copyrighted.

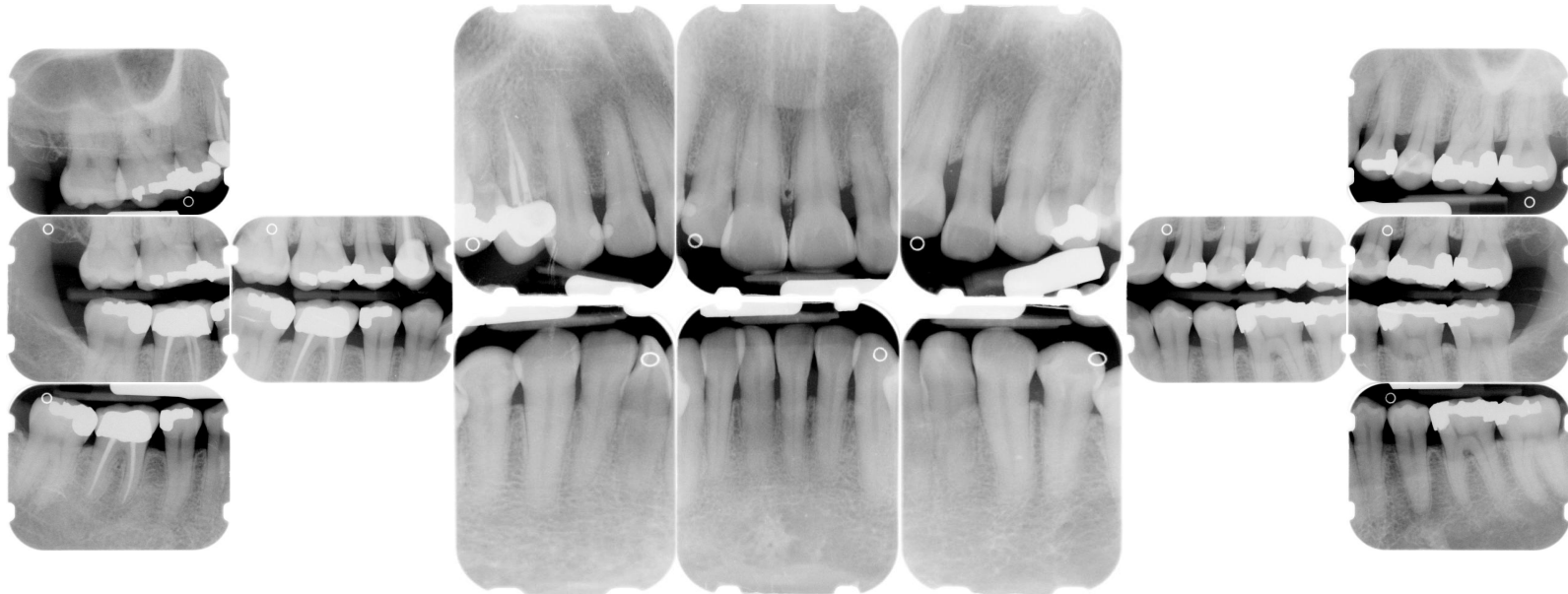
Age:
51 F

Medical History:
No meds
No problems

Dental History:
It has been 2 years since last dental visit.

Xrays before treatment:

You can click on any pic to see a larger view



Intraoral pics before tx:

Perio Charting:

Date	1	2	3	4	5	6	7	8	9	10	11	12	13	14	15	16
B		5 4 5	5 4 5	5 4 4	4 4 4	4 3 3	3 3 3	3 2 3	3 2 3	3 2 3	3 2 2	3 3 4	4 4 5	5 4 5	5 4 5	
L		5 4 5	5 4 5	5 4 5	5 4 5	4 4 4	4 4 4	4 4 4	4 4 4	4 4 4	4 4 4	5 4 5	5 4 5	5 4 5	5 4 5	
		5 4 5	5 3 5	5 3 4	4 3 3	3 3 3	3 3 3	3 3 3	3 3 3	3 3 3	3 3 4	4 3 4	4 3 4	4 3 5	5 3 5	5 3 5
		5 4 5	5 4 4	4 3 4	4 3 4	4 3 3	3 3 3	3 3 3	3 3 3	3 3 3	3 3 3	3 3 4	4 4 4	4 4 5	5 4 5	5 4 5
B		5 4 5	5 4 5	5 4 4	4 4 4	4 3 4	4 3 4	4 3 4	4 3 4	4 3 4	4 3 4	4 4 4	4 4 4	4 4 5	5 4 5	
		5 4 5	5 4 5	5 3 4	4 3 4	4 3 3	3 3 3	3 3 3	3 3 3	3 3 3	3 3 3	3 3 4	4 3 4	4 3 5	5 3 4	
	32	31	30	29	28	27	26	25	24	23	22	21	20	19	18	17

Summary Data Comparison

Date	Bleeding		Suppuration		Furcation		Mobility	PD > Alert		CAL < 0		CAL 1-3		CAL 4-5		CAL 6+	
	Teeth	Sites	Teeth	Sites	Teeth	Sites	Teeth	Teeth	Sites	Teeth	Sites	Teeth	Sites	Teeth	Sites	Teeth	Sites
	0	0	0	0	0	0	0	28	143	0	0	13	25	28	143	0	0
	9	28	0	0	0	0	0	21	86	0	0	25	82	21	86	0	0

Treatment:

- Initial appt with dentist (from this point on, only covering the hygiene appts.)
- 2nd appt. Gross Debridement - 04355
 Perio charted
 Pt has heavy burnished calculus that is very hard to remove
 Pt had gone to a different office that recommended SRP but she refused
 Generalized papillary inflammation
 Mod. Plaque, stain and subgingival calculus
 Mod hemo w/scaling
 Pt doesn't speak English very well. Printed out OHI in her language off of www.dentalcare.com Pt agreed to have SRP done.
 Peridex was given and instructions for use
- 3rd appt -- SRP UL, LL
 Anesthesia was administered
 Pt had tx done with dentist prior to my appt. Was so tired, she was not sitting still, tried to do the best I could.
 Gen. inflammation
 It plaque, mod stain and mod subgingival calculus
 Mod hemo w/scaling
 Ultrasonics and handscaling were used
- 4th appt -- SRP UR, LR
 Anesthesia was administered
 Heavy plaque , heavy tenacious subgingival on right side
 Heavy hemo w/scaling
 Reviewed homecare as left side had heavy plaque accumulation
 Did the best I could, pt would not sit still and said her neck hurt and kept closing her mouth - very difficult

appt.

need to check for residual @ NA

Rec. to pt and pt was scheduled for a 4 week re-eval appt.

- Pt cancels appts 3 times
- 5th visit -- Perio maintenance -- 04910
This is now 9 months after initial SRP
Pt stated that if insurance won't cover her appt, we should not charge her for her 3 MRC
Exp to pt that we cannot do this and went over how important it is to keep 3 MRC to keep periodontal disease stable. Pt refuses if she has to pay.
Pt not keeping up with homecare.
Heavy supragingival calculus on linguals of mand. anteriors
Extremely heavy plaque -- teeth were completely covered with heavy plaque
Ultrasonics and hand scale used.
Extremely heavy hemo w/scaling
Referral was given to pt to see periodontist and exp that she needs to see periodontist for further therapy to control disease. Pt does not want to comply with what I recommended and exp to pt that unfortunately that I cannot control her disease alone, she needs to comply with homecare and come in for regular maintenance appts. I exp that an appt every 9 months will not stabilize the disease and further bone loss can occur. Pt not happy but does make appt. with periodontist.
- NA depends on periodontist recommendation.

What would you have done in this case?

Please leave let me know by emailing me to amyrdh@aol.com.

