

Case Study #30

DISCLAIMER: These pictures are original and are **NOT** to be used anywhere else **WITHOUT Lory Laughter's written permission**. Not on any website, publication, etc. This site is now officially copyrighted.

Case presented by:
Lory Laughter, RDH, BS
momylaugh@aol.com
Napa, CA

This is not really a case study, because I have the diagnosis, but it is very interesting.

This is a 70 year old woman with Spongy Nevus. Not nevi, because it is one huge nevus that completely encompasses her oral cavity. She was diagnosed in 1948 at Mayo clinic. Most of the early 1960's pictures in journals of spongy nevus are her.

She was born with the condition and when she was 3 days old it was biopsied. The docs told her mother she would not live. But, she did. And then she got the correct diagnosis in 1948.

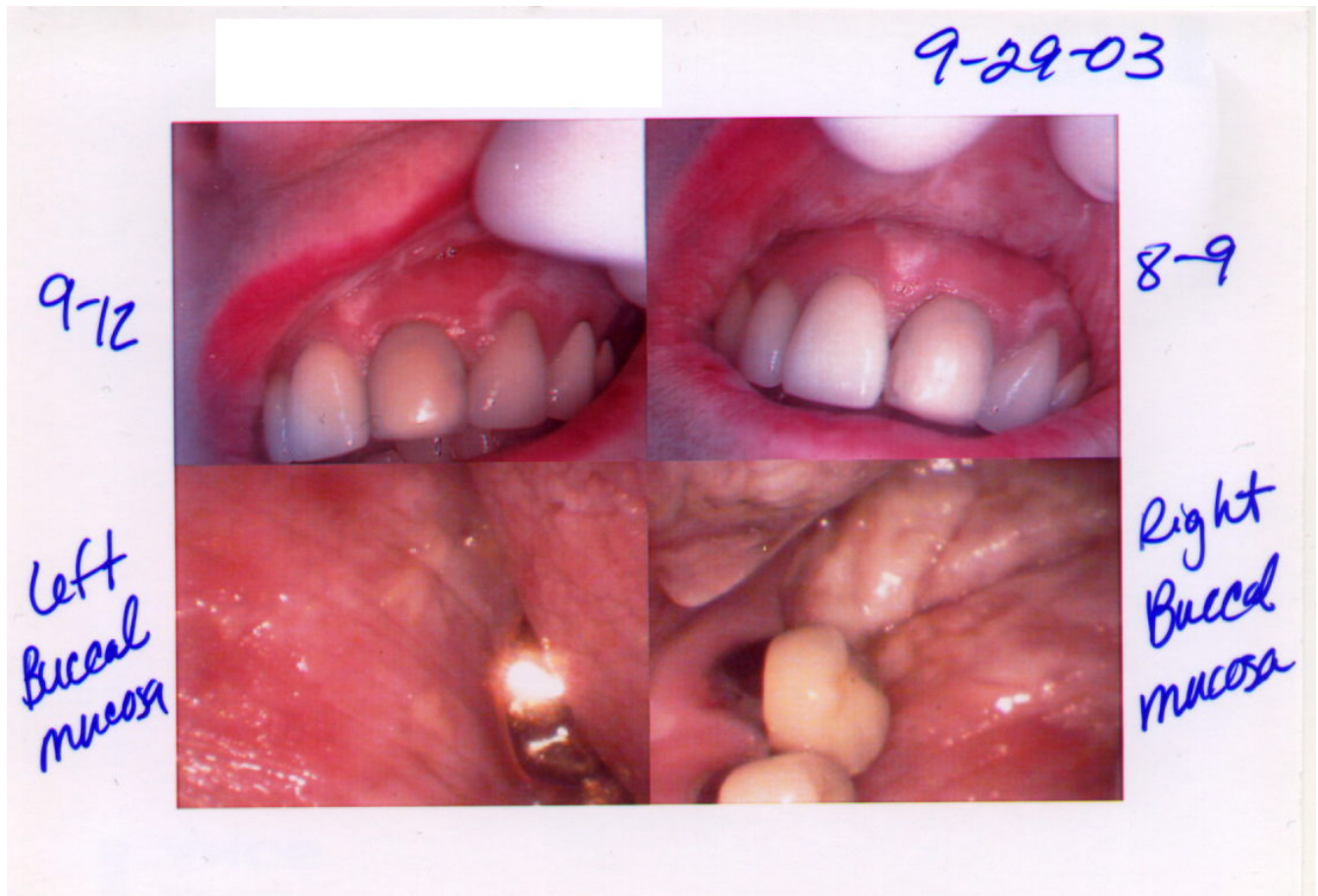
On the picture of the lower right buccal mucosa you can see the lateral border of the tongue on the upper left side. Almost her entire tongue is covered by the nevus. She has almost no stretch to her cheeks.

Also, if you look close at the anterior pictures, you can tell that the mucosa inside the upper lip is all nevus.

She was not wild about sharing this again, but agreed because I told her many students never see this. Heck, this is the first time I have ever seen nevus like this.

Lory Laughter, RDH, BS

You can click on the pictures below to see a bigger view:



What would you have done in this case?

Please leave let me know by emailing me to amyrdh@aol.com.

