

## Case Study #28

**DISCLAIMER:** These pictures are original and are **NOT** to be used anywhere else **WITHOUT my written permission.** Not on any website, publication, etc. This site is now officially copyrighted.

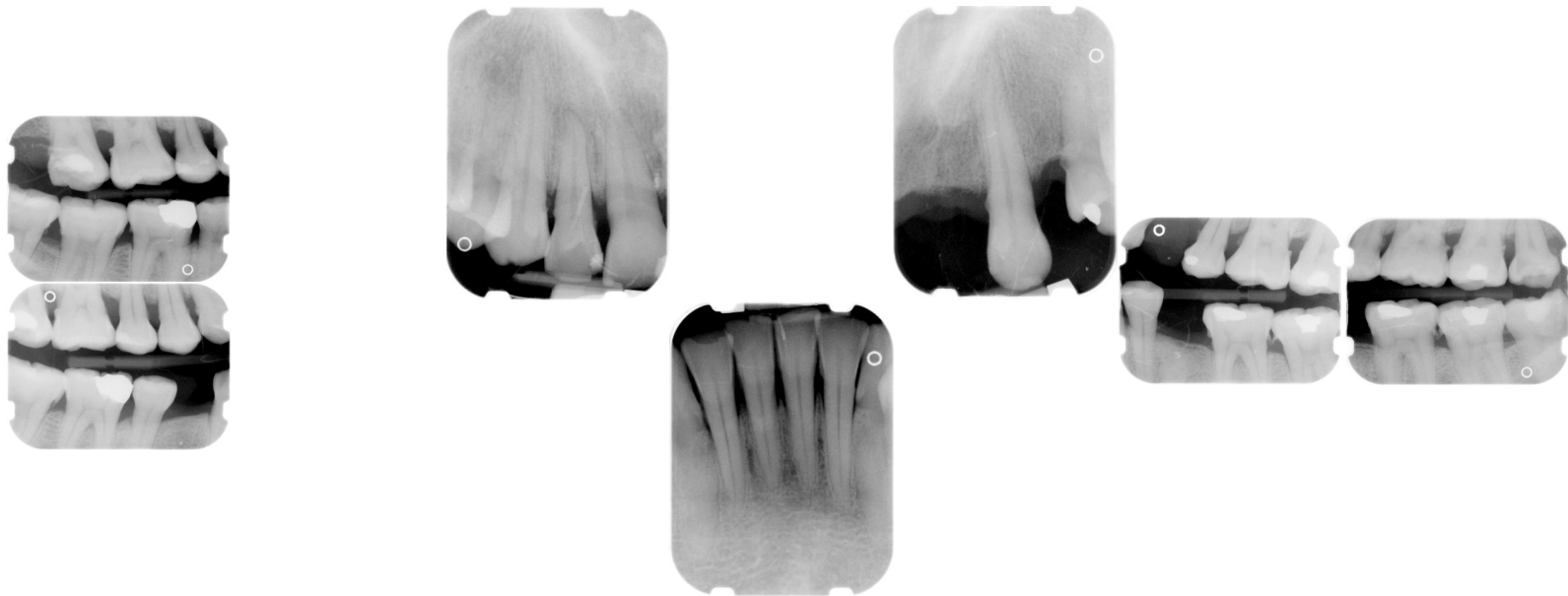**Age:**  
44 F

**Medical History:**  
Past history of smoking  
No other medical problems

**Dental History:**  
Has not been to the dentist in years.

### Xrays before treatment:

You can click on any pic to see a larger view



### Intraoral pics before tx:

None for this pt. sorry :(  
I took them but the computer crashed :(

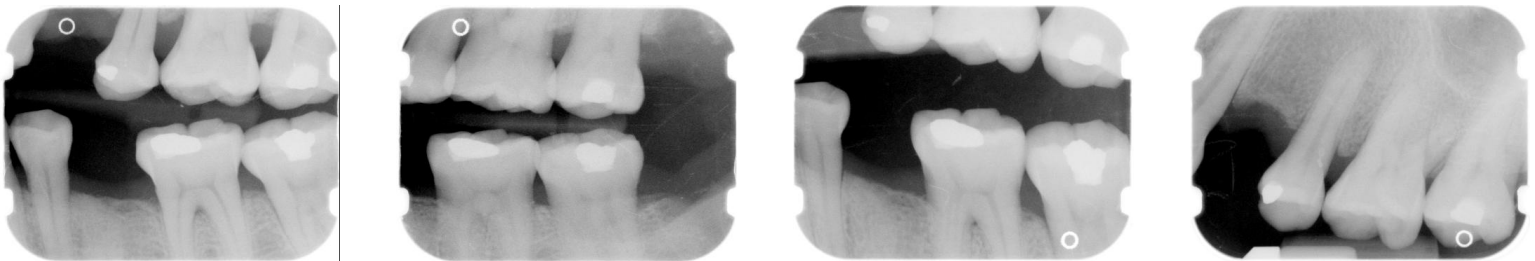
### Perio Charting:

Date	1	2	3	4	5	6	7	8	9	10	11	12	13	14	15	16
		6 4 5	5 4 5	5 4 5	5 4 3	5 4 5	5 4 6	6 4 5			5 4 5		5 4 5	5 4 5	5 4 6	6 5 5
		6 5 6	6 5 6	6 4 6	6 4 5	5 4 5	5 4 5	5 4 5			5 4 5		5 4 5	5 4 5	5 5 6	6 6 6
	5 4 5	5 4 5	5 4 5	5 4 5		4 4 4	4 4 4	4 4 4	4 4 4	4 4 4	4 4 4	4 4 4		5 4 6	6 6 6	6 6 7
	6 4 6	6 4 5	5 4 5	5 5 5		5 4 6	6 4 6	6 4 4	4 4 4	4 4 4	4 4 6	4 4 4		4 4 6	6 4 6	6 4 6
	32	31	30	29	28	27	26	25	24	23	22	21	20	19	18	17

Summary Data Comparison

Date	Bleeding		Suppuration		Furcation		Mobility		PD > Alert		CAL < 0		CAL 1-3		CAL 4-5		CAL 6+	
	Teeth	Sites	Teeth	Sites	Teeth	Sites	Teeth	Sites	Teeth	Sites	Teeth	Sites	Teeth	Sites	Teeth	Sites	Teeth	Sites
	26	156	0	0	2	2	0		26	155	0	0	1	1	26	87	24	68

Xrays after 1st treatment:



Treatment:

- Initial exam, FMX with dentist  
From this point on just speaking of hygiene appts.
- 1st visit -- Gross debridement -- 04355  
Perio charted -- I don't think the readings were true due to the heavy ledges that were present on the teeth.
- 2nd visit -- SRP UL, LL -- 04341 (2 quads)  
Anesthesia administered  
Very hard tenacious calculus, on this case, predominately used the ultrasonic due to heavy black THICK ledges. I used the Hu-Friedy black hub swivel tip and it helped me out to crush up the thick ledges. It saved me!  
Mod hemo w/scaling  
This pt was do difficult (but oh so sweet!) that I took digital bwx after (Due to how heavy this calculus was and how the teeth were angled) to make sure there wasn't any residual left over. I was so shocked on how smooth all the surfaces felt with all the calculus that was present.
- This case is ongoing -- pt needs 2 more quads completed.

What would you have done in this case?

Please leave let me know by emailing me to [amyrdh@aol.com](mailto:amyrdh@aol.com).

