

## Case Study #25

**DISCLAIMER:** These pictures are original and are **NOT** to be used anywhere else **WITHOUT my written permission**. Not on any website, publication, etc. This site is now officially copyrighted.

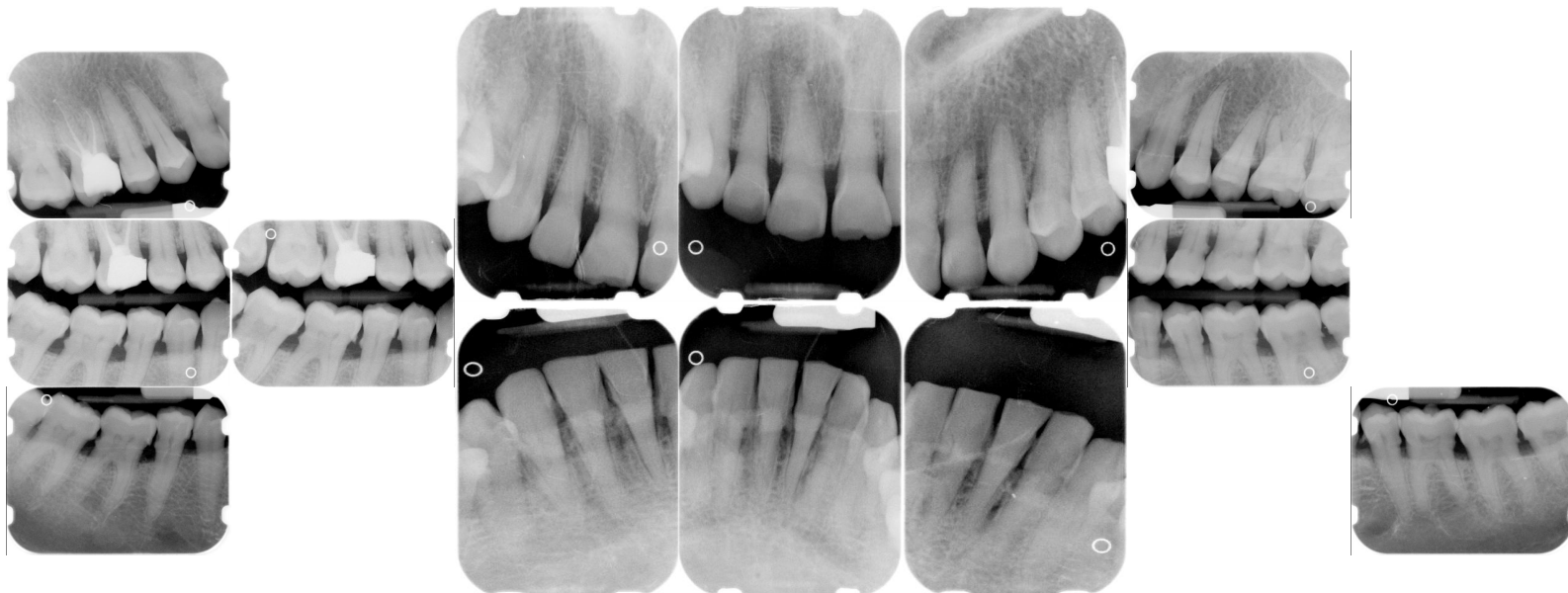
Age:  
64 F

Medical History:  
Smoker

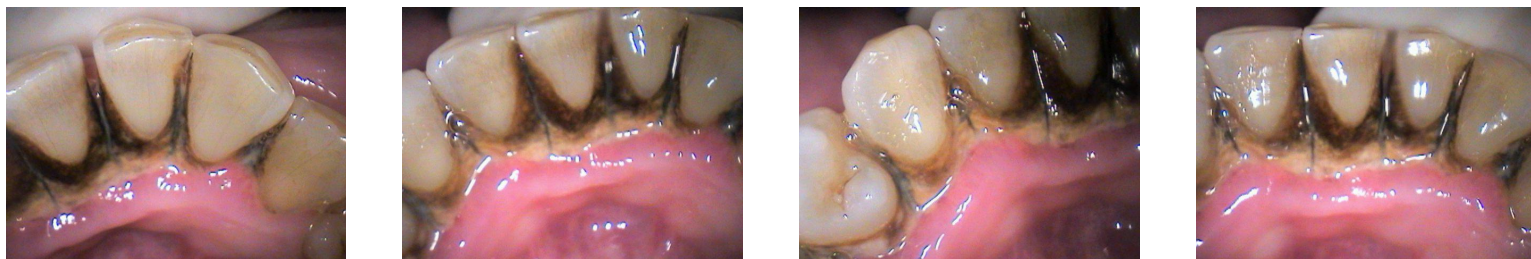Dental History (Hygiene)  
Pt has never had her teeth  
"professionally" cleaned.  
Apprehensive.

### Xrays before treatment:

You can click on any pic to see a larger view



### Intraoral pics before tx:



### Perio Charting:

No perio charting done on first visit due to heavy supragingival calculus and pt being so hypersensitive.

### Xrays after tx:

Coming soon

Coming soon

### Treatment:

- Initial appt with dentist (from this point on, only covering the hygiene appts.)
- 1st -- Gross Debridement - 4355  
perio charting -- will have to do perio charting @ NA appt. due to not being able to with such heavy calculus. Also pt was hypersensitive.  
Ultrasonic was predominately used, supragingival only -- calculus was VERY thick and tenacious!  
Heavy generalized calculus, heavy stain  
Chlorhexidine and instructions for use given  
OHI  
Intraoral pictures taken
- Treatment ongoing, will keep everyone updated.

What would you have done in this case?

Please leave let me know by emailing me to [amyrdh@aol.com](mailto:amyrdh@aol.com).

