

Case Study #23

DISCLAIMER: These pictures are original and are **NOT** to be used anywhere else **WITHOUT my written permission**. Not on any website, publication, etc. This site is now officially copyrighted.

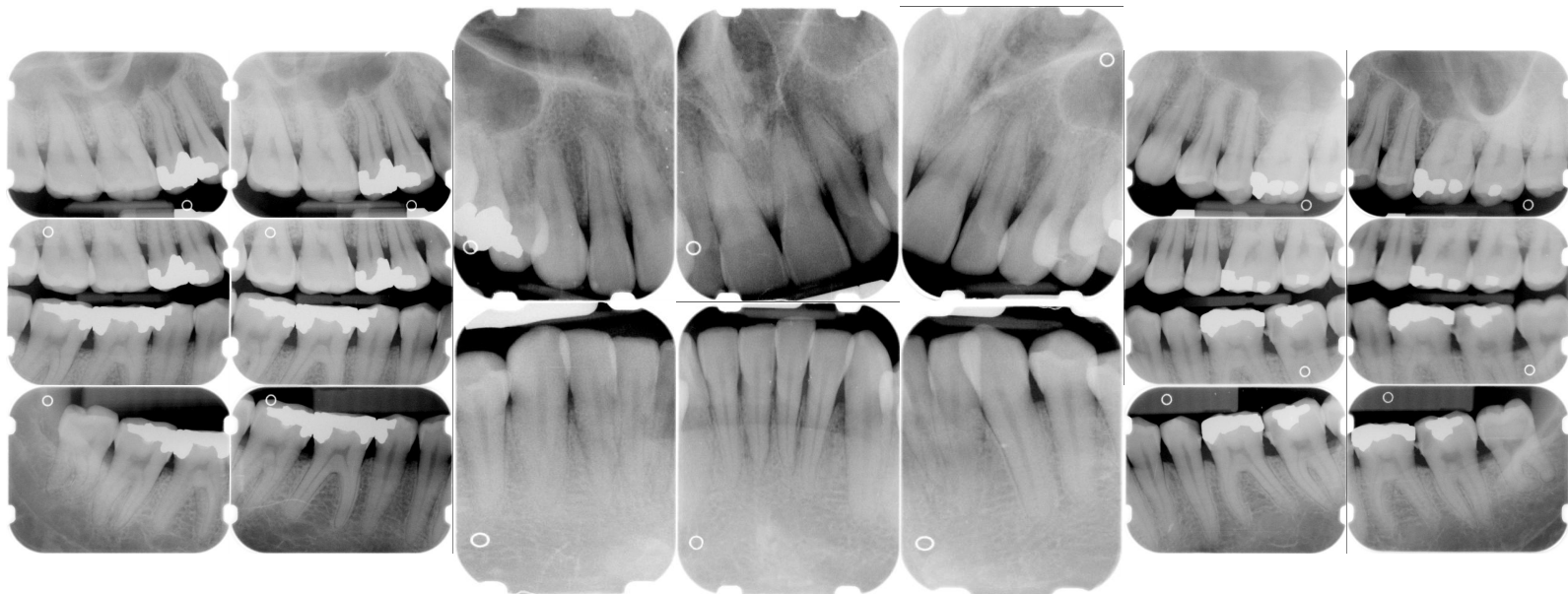
Age:
32 M

Medical History:
No problems, meds
Smoker

Dental History:
Pt's last dental visit was 10 years ago in Russia.
Pt stated he was never told that he had periodontal disease.
No history of periodontal therapy.

Xrays before treatment:

You can click on any pic to see a larger view



Intraoral pics before tx:

None for this pt. sorry :(

Perio Charting:

Date	1	2	3	4	5	6	7	8	9	10	11	12	13	14	15	16
	5 4 5	5 4 5	5 4 4	4 3 4	4 3 3	3 2 3	3 2 3	3 2 3	3 2 3	3 2 3	3 2 5	4 2 4	4 3 4	3 4 5	5 3 4	5 4 4
	5 4 5	5 4 4	5 4 5	4 4 5	5 4 4	4 2 3	3 2 3	3 2 3	3 2 3	3 2 3	3 2 3	4 3 4	4 3 3	4 4 5	4 4 5	5 4 3
	6 4 5	5 5 6	6 4 4	4 2 3	3 2 3	3 2 3	3 2 3	4 2 3	3 2 3	3 2 3	3 2 3	3 3 4	4 4 4	4 4 5	5 4 5	4 4 6
	5 4 4	6 4 4	4 4 4	4 2 3	3 2 4	3 2 4	4 2 3	3 2 3	3 2 3	3 2 3	3 2 3	3 3 3	3 3 4	4 4 5	5 4 6	5 5 5
	<u>32</u>	<u>31</u>	<u>30</u>	<u>29</u>	<u>28</u>	<u>27</u>	<u>26</u>	<u>25</u>	<u>24</u>	<u>23</u>	<u>22</u>	<u>21</u>	<u>20</u>	<u>19</u>	<u>18</u>	<u>17</u>

Summary Data Comparison

Date	Bleeding		Suppuration		Furcation		Mobility	PD > Alert		CAL < 0		CAL 1-3		CAL 4-5		CAL 6+	
	Teeth	Sites	Teeth	Sites	Teeth	Sites	Teeth	Teeth	Sites	Teeth	Sites	Teeth	Sites	Teeth	Sites	Teeth	Sites
	27	122	0	0	0	0	0	25	98	0	0	21	78	28	106	6	8

Xrays after tx:

Treatment ongoing

Treatment ongoing

Treatment:

- Initial exam, FMX with dentist
From this point on just speaking of hygiene appts.
Pt max. teeth are sensitive
Gen. inflammation
Heavy plaque, heavy gen. tobacco stain, mod. gen. subgingival calculus, mod. supragingival calculus on mand. anterior
Mod. hemo w/ probing
Moderate periodontal disease, moderate recession
OHI -- pt brushes 2x a day but doesn't floss, stressed daily. Gave pt folder with information and articles on periodontal disease. Exp periodontal disease, etiology of and disease process. Gave pt chlorhexidine and instructions for use.
Rec. oral-b 3-D toothbrush.
- 2nd visit -- SRP UR -- 04341
Anesthesia administered
gen. inflammation
heavy subgingival calculus, mod stain
heavy hemo w/scaling
Rev. OHI
- 3rd visit -- SRP UL, LL -- 04341 (2 quads)
Anesthesia was administered
gen. inflammation
heavy subgingival calculus, mod stain

heavy hemo w/scaling
Rev. OHI

- This case is ongoing -- pt needs 1 more quad completed.

What would you have done in this case?

Please leave let me know by emailing me to amyrdh@aol.com.

