

Case Study #20

DISCLAIMER: These pictures are original and are **NOT** to be used anywhere else **WITHOUT my written permission**. Not on any website, publication, etc. This site is now officially copyrighted.

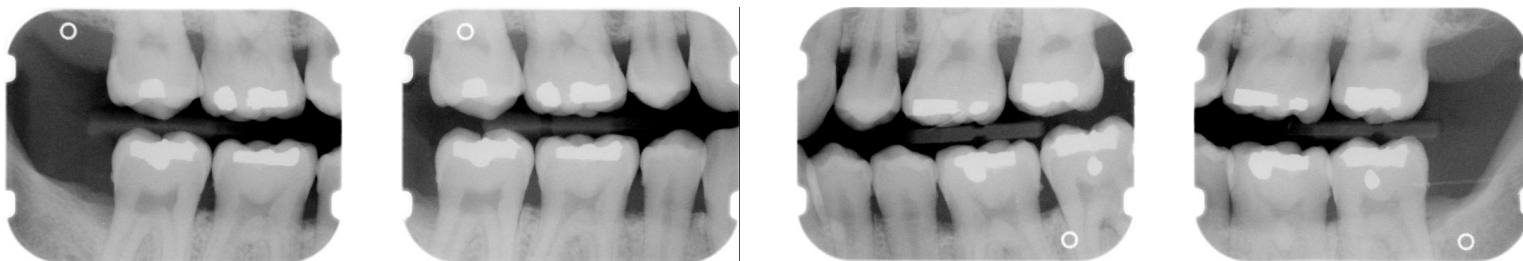
Age:
35 M

Medical History:
No problems, meds
Non-smoker, but has smoked in the past.

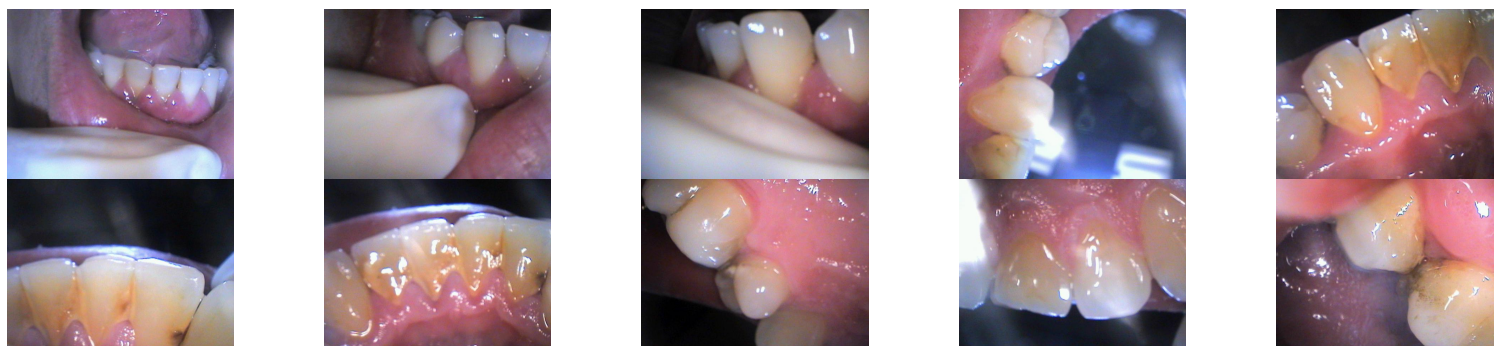Dental History:
Pt had braces.
Last prophy was 5 years ago when pt had braces removed.
Did have an FMX taken at another office about a year ago -- no tx. was done at that time.

Xrays before treatment:

You can click on any pic to see a larger view



Intraoral pics before tx:



Perio Charting:

| Date | 1 | 2 | 3 | 4 | 5 | 6 | 7 | 8 | 9 | 10 | 11 | 12 | 13 | 14 | 15 | 16 |
|------|---|-------|-------|-------|---|-------|-------|-------|-------|-------|-------|----|-------|-------|-------|----|
| B | | 5 4 5 | 5 4 5 | 5 4 5 | | 4 3 4 | 4 3 4 | 4 3 3 | 3 3 5 | 5 4 5 | 5 4 4 | | 4 4 5 | 5 4 5 | 5 4 5 | |
| L | | 5 4 6 | 5 4 5 | 5 4 5 | | 3 3 3 | 3 3 3 | 3 3 4 | 4 4 4 | 4 4 5 | 5 4 4 | | 5 4 5 | 5 4 5 | 5 4 6 | |

| | | | | | | | | | | | | | | | | |
|---|--|-------|-------|-------|--|-------|-------|-------|-------|-------|-------|-------|-------|-------|-------|--|
| L | | 5 5 5 | 5 4 5 | 5 4 5 | | 4 3 4 | 4 3 4 | 4 3 4 | 4 3 4 | 4 3 4 | 4 3 4 | 5 4 5 | 5 4 5 | 5 4 6 | 6 5 6 | |
|---|--|-------|-------|-------|--|-------|-------|-------|-------|-------|-------|-------|-------|-------|-------|--|

| | | | | | | | | | | | | | | | | | |
|---|--|-----------|-----------|-----------|-----------|-----------|-----------|-----------|-----------|-----------|-----------|-----------|-----------|-----------|-----------|-----------|-----------|
| B | | 5 4 5 | 5 4 5 | 5 4 5 | | 4 4 4 | 4 4 4 | 4 4 4 | 4 4 4 | 4 4 4 | 4 4 4 | 4 4 5 | 5 4 5 | 5 4 5 | 5 4 6 | | |
| | | <u>32</u> | <u>31</u> | <u>30</u> | <u>29</u> | <u>28</u> | <u>27</u> | <u>26</u> | <u>25</u> | <u>24</u> | <u>23</u> | <u>22</u> | <u>21</u> | <u>20</u> | <u>19</u> | <u>18</u> | <u>17</u> |

Summary Data Comparison

| Date | Bleeding | | Suppuration | | Furcation | | Mobility | PD > Alert | | CAL < 0 | | CAL 1-3 | | CAL 4-5 | | CAL 6+ | |
|------|----------|-------|-------------|-------|-----------|-------|----------|------------|-------|---------|-------|---------|-------|---------|-------|--------|-------|
| | Teeth | Sites | Teeth | Sites | Teeth | Sites | Teeth | Teeth | Sites | Teeth | Sites | Teeth | Sites | Teeth | Sites | Teeth | Sites |
| | 20 | 111 | 0 | 0 | 0 | 0 | 0 | 25 | 130 | 0 | 0 | 10 | 20 | 25 | 124 | 4 | 6 |

Treatment:

- Initial visit with dentist, FMX
From this point on, just discussing hygiene appts.
Perio charted
Gen. inflammation, boggy, papillary inflammation
mod. supragingival calculus, heavy black tenacious subgingival calculus
mod - heavy hemo w/probing
3-6 mm pockets -- localized periodontal disease
OHI -- exp about gingivitis and periodontal disease, etiology of and disease process, showed pt areas of bone loss on xrays and explained perio charting, stressed daily flossing. Gave pt chlorhexidine and instructions for use
- SRP UL, LL -- 04341 (2 quads)
Anesthesia was administered, pt had trouble getting numb
gen. inflammation, bulbous papilla
It plaque, heavy tenacious calculus -- extremely hard to remove and areas that need to be rechecked are distals of 18, 19, 20 and 21
Extremely heavy hemo w/scaling
Pt was given ibuprofen before he left due to aggressive scaling
rec. warm salt water rinses at home
- SRP UR -- 04341
Anesthesia was administered
Pt stated he was sore for a day after last tx.
It inflammation
heavy subgingival calculus, mod plaque
extremely heavy hemo w/scaling
OHI -- stressed continued homecare

- SRP LR -- 04341
Anesthesia was administered
pt stated he was ok after last tx.
It bulbous inflammation -- other quads look good!
heavy tenacious calculus, still feels rough on #29 M and 31 D
Heavy hemo w/scaling
Rec. sonicare, pt bought sonicare today (family model for him and his wife)
- Fine scale / Re-eval
still some papillary inflammation
pockets 2- 5 mm
It plaque, It subgingival calculus on areas needed to be checked as noted from SRP
It - mod hemo
- Perio maintenance -- 04910 -- on 4 MRC
pt. wants a referral for orthodontist to get a new retainer, referral given.
It marginal inflammation
Lt plaque, It calculus on linguals of mand. anteriors
mod hemo w/scaling -- questioned pt about meds, not on any meds., pt not flossing but is using sonicare
OHI -- flossing
- Will keep this case updated -- one of my favorite patients!!!! :))

What would you have done in this case?

Please leave let me know by emailing me to amyrdh@aol.com.

