

Case Study #19

DISCLAIMER: These pictures are original and are **NOT** to be used anywhere else **WITHOUT my written permission**. Not on any website, publication, etc. This site is now officially copyrighted.

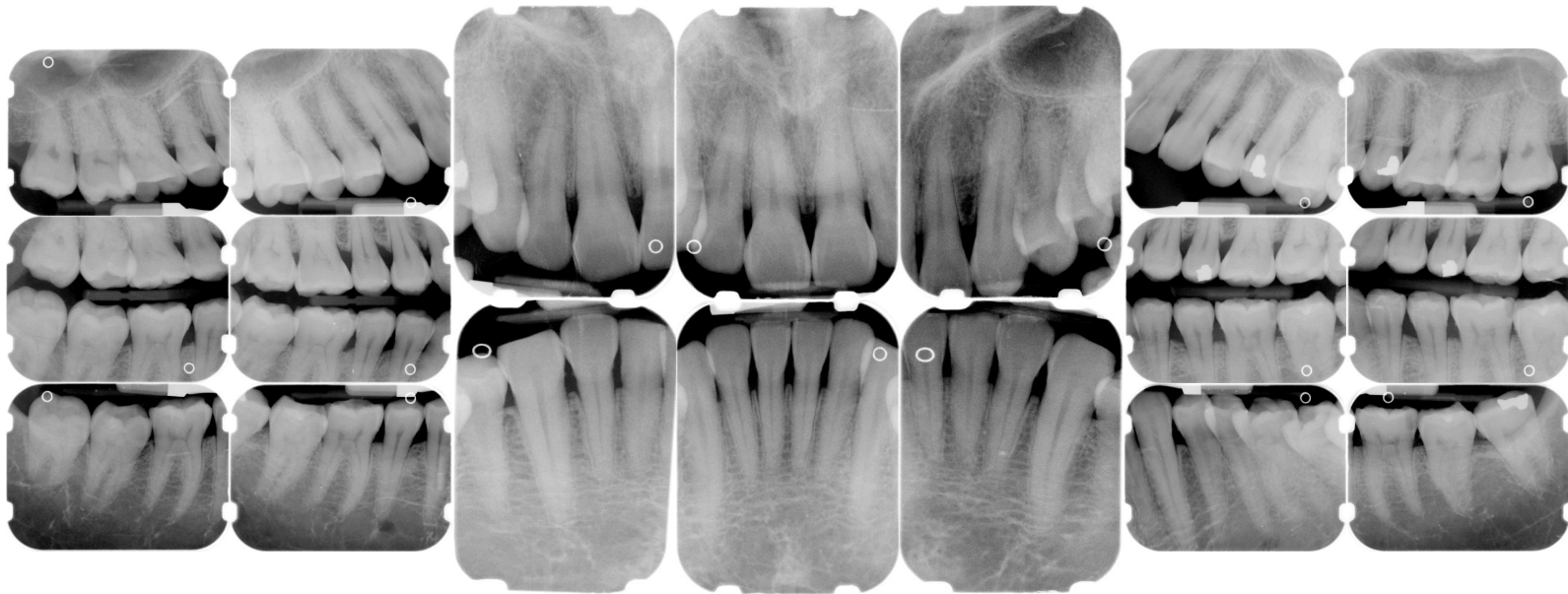
Age:
45 M

Medical History:
No problems, meds
smoker

Dental History:
Last prophy was 9 months ago.
Pt was on a regular 6 month schedule @
other office.
Pt stated other office only took 20
minutes to "clean" his teeth every 6
months.

Xrays before treatment:

You can click on any pic to see a larger view



Intraoral pics before tx:

None on this pt, sorry :(

Perio Charting:

Date	1	2	3	4	5	6	7	8	9	10	11	12	13	14	15	16
	5 3 5	5 3 5	5 3 5	5 3 5	5 3 5	4 4 4	3 2 3	3 2 3	3 2 3	3 2 4	4 2 4	3 2 4	4 2 4	4 2 5	5 2 5	5 4 5
	5 5 5	5 3 5	5 3 5	4 3 4	4 3 4	3 2 3	3 2 3	3 2 3	3 2 3	3 2 3	3 2 3	3 2 4	4 3 4	4 3 4	4 3 5	5 3 5
	6 5 5	5 4 5	5 4 5	4 4 4	4 4 4	3 2 3	3 2 3	3 2 3	3 2 3	3 2 3	3 2 4	5 4 5	4 4 5	5 4 5	5 4 6	6 6 6
	5 4 5	5 3 4	4 3 4	4 3 4	4 3 3	3 3 4	3 2 3	3 2 3	3 2 3	3 2 3	3 2 4	4 3 3	4 2 4	4 3 4	4 3 5	5 3 5
	<u>32</u>	<u>31</u>	<u>30</u>	<u>29</u>	<u>28</u>	<u>27</u>	<u>26</u>	<u>25</u>	<u>24</u>	<u>23</u>	<u>22</u>	<u>21</u>	<u>20</u>	<u>19</u>	<u>18</u>	<u>17</u>

Summary Data Comparison

Date	Bleeding		Suppuration		Furcation		Mobility	PD > Alert		CAL < 0		CAL 1-3		CAL 4-5		CAL 6+	
	Teeth	Sites	Teeth	Sites	Teeth	Sites	Teeth	Teeth	Sites	Teeth	Sites	Teeth	Sites	Teeth	Sites	Teeth	Sites
	24	83	0	0	0	0	0	25	98	0	0	31	94	25	93	3	5

Treatment:

- Initial visit with dentist, FMX
From this point on, just discussing hygiene appts.
Gen. inflammation
Heavy IP plaque, mod stain, mod calculus both supragingival and subgingival
2-6 mm pockets, perio charting recorded on computer today
OHI -- flossing, exp disease process, etiology of perio disease, exp to pt that he has early - mod localized areas of periodontal disease
pt given chlorhexidine
- SRP UL, LL -- 04341 (2 quads)
Administered anesthesia -- pt apprehensive about needle
still gen. inflammation
very tenacious calculus, heavy stain
Extremely heavy hemo w/scaling
OHI -- pt was given Omnii compliance kit to use at home
- SRP UR, LR -- 04341 (2 quads)
Administered anesthesia
Heavy tenacious subgingival calculus
OHI
- Perio maintenance -- 04910
inflammation still present
mod plaque, mod food impaction, It calculus
Mod hemo w/scaling
OHI
- Perio maintenance -- 04910 -- on 3 MRC

inflammation still present
It plaque, It calculus, It stain
Mod hemo w/scaling
OHI

- will keep this case updated.

What would you have done in this case?

Please leave let me know by emailing me to amyrdh@aol.com.

