

Case Study #18

DISCLAIMER: These pictures are original and are **NOT** to be used anywhere else **WITHOUT my written permission**. Not on any website, publication, etc. This site is now officially copyrighted.

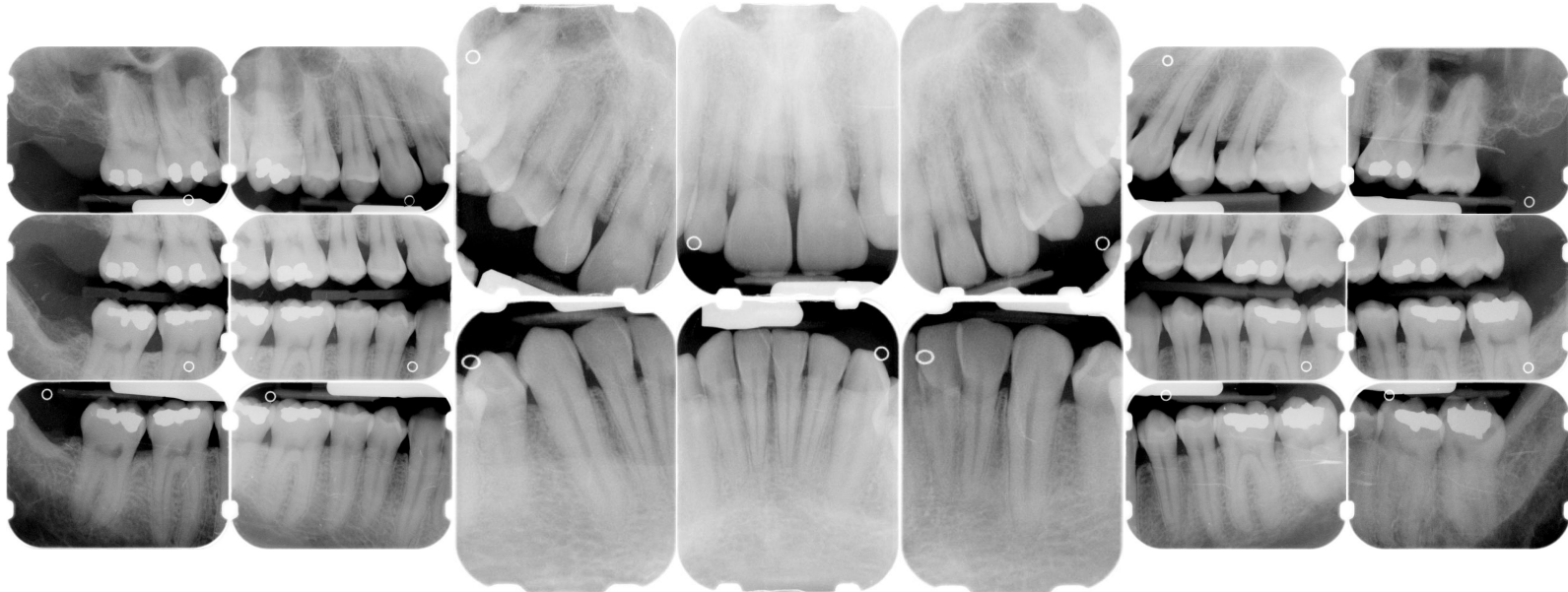
Age:
37 M

Medical History:
No problems, meds
Smoker

Dental History:
It has been 11-12 years since last dental visit.

Xrays before treatment:

You can click on any pic to see a larger view



Intraoral pics before tx:

None on this pt sorry :(

Perio Charting:

| Date | 1 | 2 | 3 | 4 | 5 | 6 | 7 | 8 | 9 | 10 | 11 | 12 | 13 | 14 | 15 | 16 |
|------|-----------|-----------|-----------|-----------|-----------|-----------|-----------|-----------|-----------|-----------|-----------|-----------|-----------|-----------|-----------|-----------|
| | | 5 4 5 | 5 4 5 | 5 4 5 | 5 4 5 | 4 3 4 | 4 2 3 | 3 2 2 | 2 2 2 | | 3 2 3 | 3 3 4 | 4 3 5 | 5 4 5 | 5 4 5 | |
| | | 5 4 5 | 5 4 5 | 5 4 5 | 5 4 4 | 4 3 3 | 3 3 4 | 4 3 4 | 4 3 3 | | 4 3 4 | 4 4 5 | 5 4 5 | 5 4 5 | 5 5 6 | |
| | | 5 4 5 | 5 4 5 | 5 4 5 | 5 4 4 | 3 3 3 | 3 3 3 | 3 3 3 | 3 3 3 | 3 3 3 | 3 3 4 | 4 4 5 | 5 4 5 | 5 4 5 | 5 4 5 | |
| | | 5 4 5 | 5 4 5 | 5 4 5 | 5 4 5 | 4 3 4 | 4 3 4 | 4 3 4 | 4 3 4 | 4 3 4 | 4 3 4 | 4 4 4 | 4 4 5 | 5 4 5 | 5 4 5 | |
| | <u>32</u> | <u>31</u> | <u>30</u> | <u>29</u> | <u>28</u> | <u>27</u> | <u>26</u> | <u>25</u> | <u>24</u> | <u>23</u> | <u>22</u> | <u>21</u> | <u>20</u> | <u>19</u> | <u>18</u> | <u>17</u> |

Summary Data Comparison

| Date | Bleeding | | Suppuration | | Furcation | | Mobility | PD > Alert | | CAL < 0 | | CAL 1-3 | | CAL 4-5 | | CAL 6+ | |
|------|----------|-------|-------------|-------|-----------|-------|----------|------------|-------|---------|-------|---------|-------|---------|-------|--------|-------|
| | Teeth | Sites | Teeth | Sites | Teeth | Sites | Teeth | Teeth | Sites | Teeth | Sites | Teeth | Sites | Teeth | Sites | Teeth | Sites |
| | 16 | 58 | 0 | 0 | 0 | 0 | 0 | 27 | 116 | 0 | 0 | 13 | 46 | 27 | 115 | 1 | 1 |

Xrays after tx:

Coming soon

Coming soon

Treatment:

- Initial visit with dentist, FMX
From this point on, just discussing hygiene appts.
Gen. inflammation, bulbous papilla, marginal inflammation, edematous
Heavy bridge of calculus on lingual of 22-27, mod - heavy gen. subgingival calculus, mod IP plaque
2-6 mm pockets, perio charting recorded on computer today
OHI -- flossing, exp disease process, etiology of perio disease, exp to pt that he has early - mod localized areas of periodontal disease
- SRP UL, LL -- 04341 (2 quads)
Administered anesthesia
still gen. inflammation
very tenacious calculus, very hard to remove, check MB of #11, DB of #13 adn DB of #14 -- still very rough
Extremely heavy hemo w/scaling
OHI
- SRP UR, LR -- 04341 (2 quads)
Administered anesthesia -- hard to get pt numb. Pt was out late the night before drinking
New calculus present on quads already SRP -- pt laughed and said he is not flossing
Mod subgingival calculus on right side, mod - heavy plaque
OHI, exp to pt that his gums are not going to heal unless he starts taking care of himself at home
- Perio maintenance -- 04910
pt was late, probed, 2-5 mm pockets, did not get to record on computer today
Mod supragingival calculus

Heavy plaque
Still heavy hemo
Rev. OHI -- pt not flossing, brushes 1x a day
Put pt on a 3 MRC due to non-compliance with homecare
Pt given folder with info and articles on periodontal disease

- Will keep this case updated

What would you have done in this case?

Please leave let me know by emailing me to amyrdh@aol.com.

