

Case Study #11

DISCLAIMER: These pictures are original and are **NOT** to be used anywhere else **WITHOUT my written permission**. Not on any website, publication, etc. This site is now officially copyrighted.

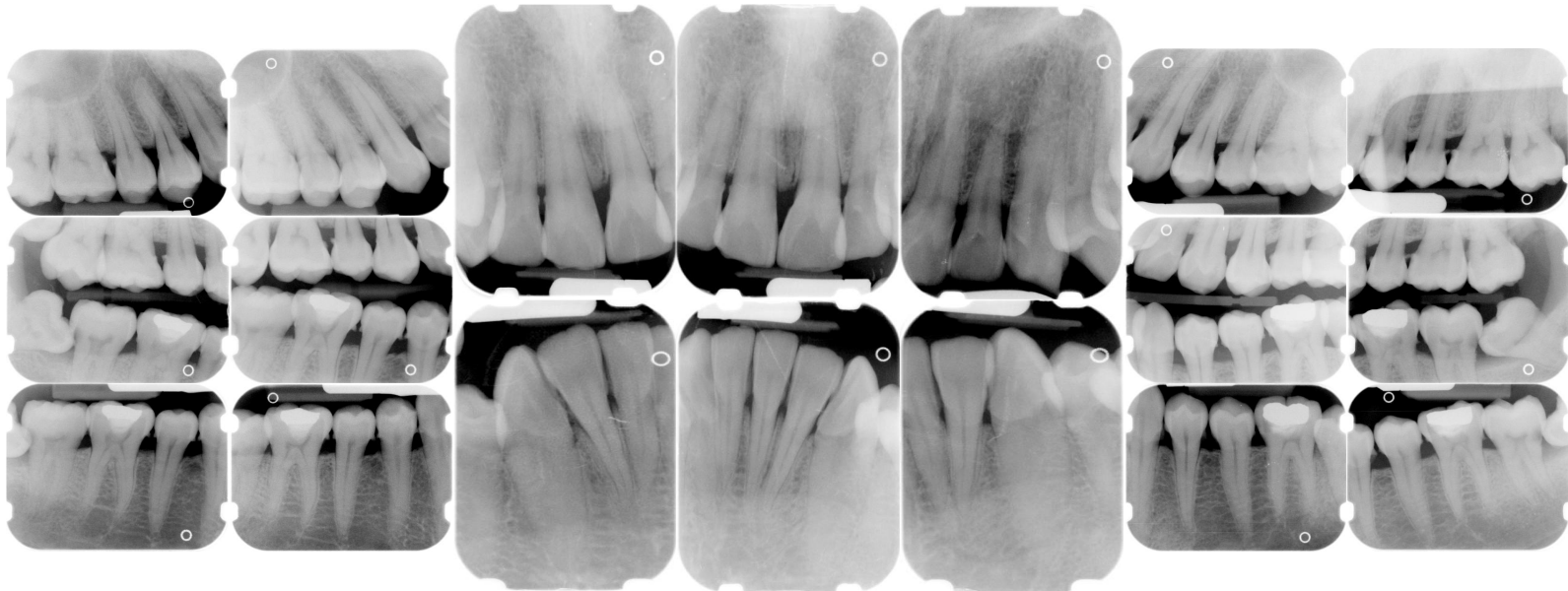
Age:
32 M

Medical History:
No problems, meds
Smoker

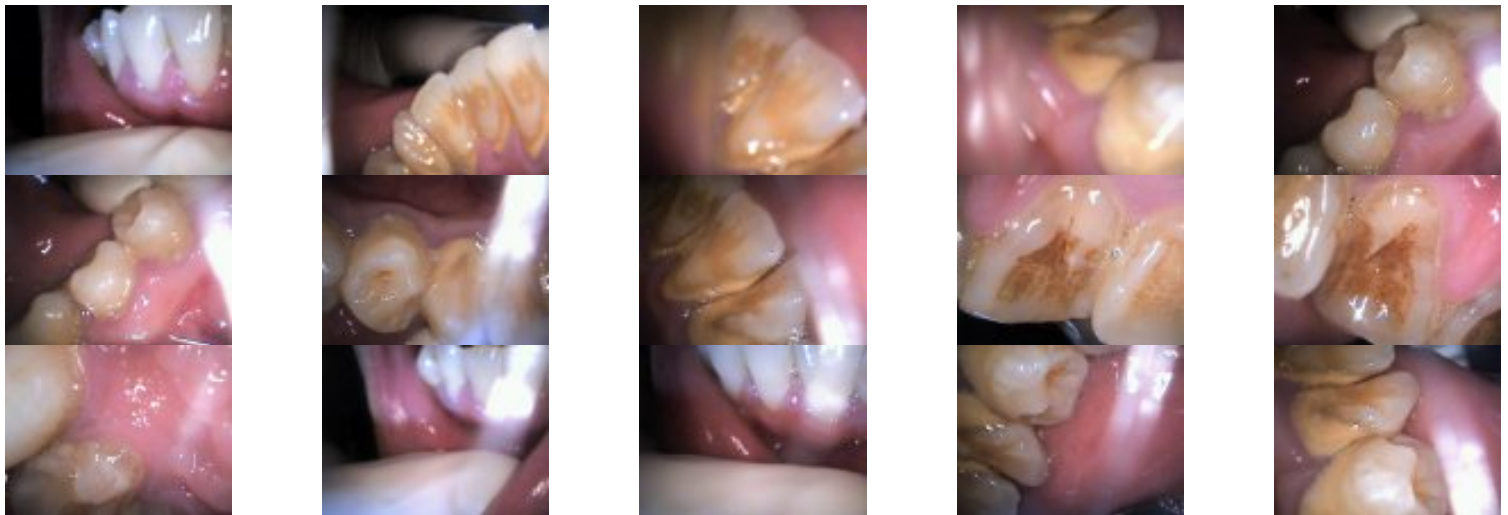Dental History:
It has been at least 7 years since last dental visit.
Apprehensive.

Xrays before treatment:

You can click on any pic to see a larger view



Intraoral pics before tx:



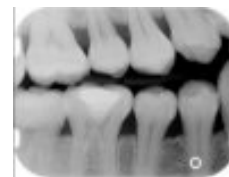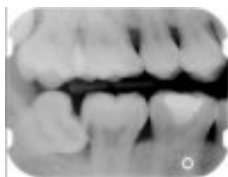Perio Charting:

Date	1	2	3	4	5	6	7	8	9	10	11	12	13	14	15	16	
		5 4 5	5 4 5	5 4 5	5 4 5	5 4 4	4 4 4	4 4 4	4 4 4	4 4 5	5 4 5	5 4 4	4 4 5	5 4 5	5 4 5		
		5 4 5	5 4 5	5 4 5	5 4 5	4 4 5	5 4 5	5 4 5	5 4 5	5 4 5	5 4 4	4 4 5	5 4 5	5 4 5	5 4 5		
		5 4 5	5 4 5	5 4 5	5 4 5	4 4 4	4 4 4	4 4 4	4 4 4	4 4 4	4 4 4	4 4 5	5 4 5	5 4 5	5 4 6	6 4 6	
		6 4 5	5 4 5	5 4 5	5 4 5	5 4 4	4 4 4	4 4 4	4 4 5	5 4 5	5 4 5	5 4 5	5 4 5	5 4 5	5 4 6	6 4 5	
		<u>32</u>	<u>31</u>	<u>30</u>	<u>29</u>	<u>28</u>	<u>27</u>	<u>26</u>	<u>25</u>	<u>24</u>	<u>23</u>	<u>22</u>	<u>21</u>	<u>20</u>	<u>19</u>	<u>18</u>	<u>17</u>

Summary Data Comparison

Date	Bleeding		Suppuration		Furcation		Mobility	PD > Alert		CAL < 0		CAL 1-3		CAL 4-5		CAL 6+	
	Teeth	Sites	Teeth	Sites	Teeth	Sites	Teeth	Teeth	Sites	Teeth	Sites	Teeth	Sites	Teeth	Sites	Teeth	Sites
	2	4	0	0	0	0	0	30	180	0	0	0	0	30	174	3	6

Xrays after tx:



Treatment:

- Initial Exam, FMX by dentist
From this point on, just discussing dental hygiene appts.
(3rd molars were rec. for ext.)
- 1st visit -- Gross Debridement -- 04355
Ultrasonic only used due to heavy supragingival calculus
Pt. apprehensive, but after today's appt was very surprised when finished with today because it did not "hurt" him.
Severe inflammation, friable after heavy supragingival calculus was removed on anteriors
Very tenacious caluclus generalized, both suprag and subg, black subg
Extremely heavy hemo w/scaling
OHI -- periodontal disease, etiology and how to control, proper homecare, brushing and flossing, regular recalls once tx is completed
- 2nd visit -- SRP UR, LR -- (2 quads 04341)
Anesthesia was administered
Pt stated he felt fine after last tx.
Very heavy tenacious subgingival calculus, very hard to remove. esp. on max.
Extremely heavy hemo w/scaling
Rev. homecare

Rec. warm salt water rinses

- 3rd visit -- SRP UL, LL -- (2 quads 04341)

Anesthesia was administered

Pt was sens. today with scaling -- placed cavity shield after tx completed.

Pt stated he felt fine after last tx.

Very heavy tenacious subgingival calculus, very hard to remove, still feel rough areas, need to check for residual @ NA

Extremely heavy hemo w/scaling

Arestin placed on 15 MD, 18 MD, and 30 MD -- written aftercare instructions and brochure given.

Rev. homecare

Rec. warm salt water rinses

- Awaiting reeval. -- will keep updated
- Ultrasonics and handscaling were used on this pt.

What would you have done in this case? Please leave let me know by emailing me to amyrdh@aol.com.

